

THORACO-LUMBAR STENOSIS

COX PART 3
NASHVILLE, TN
OCTOBER 8-9, 2011
KURT J. OLDING D.C.
MINSTER, OH

INTRODUCTION

- This case is a premium example of seeing the whole picture before clinical decisions are made.
- Dr. Cox saved this patient from having another surgery that likely would not have solved his problem.

○ “To a man with only a hammer, everything looks like a nail!”

INTRODUCTION

- This patient showed multiple levels of stenosis, but the bilateral leg weakness was an important clue that the thoraco-lumbar area should not be ignored.
- An orthopedic surgeon and a neurosurgeon initially recommended intervention at the L4/5 area only; one a decompression laminectomy and fusion and the other just decompression laminectomy.

Introduction

- Dr. Cox recommended consultation with a neurosurgeon he works with, and this neurosurgeon did a decompression laminectomy and fusion at the T11-12 segment.

HISTORY

- 52 year old male, 5'11", 298 pounds
- Lower back pain radiating into both anterior thighs after lifting handicapped daughter
- Previous history of three minor lower back episodes
- Pain levels 5/10

Physical Examination

- +Kemp's sign, negative SLR, heel and toe walk strong
- Flexion of the lumbar spine was to 90, extension increased pain

Treatment

- Cox protocol 1 treatment with galvanism to lumbar spine and sciatic notch
- A decision was made to contact L3 and the patient was tolerance tested
- The patient was 50% improved after the first visit
- Two days after the second visit suffered an acute exacerbation while walking his two large dogs

Treatment

- He reported weakness after this incident in both legs and was only comfortable when lying down.
- He went to his family physician for NSAIDs and x-rays were taken at the local hospital.
- Xrays showed degenerative arthritis at the L4/5 and L5/S1 levels.
- Pain was now in shins bilaterally.

Treatment

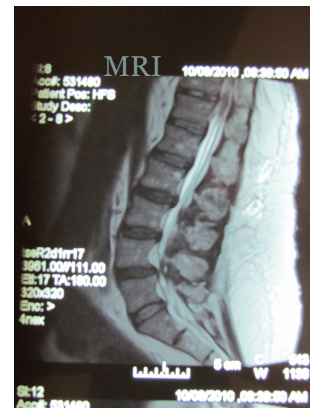- Due to the weakness, a consult was set up with orthopedic surgeon that the family chose.
- MRI was ordered.

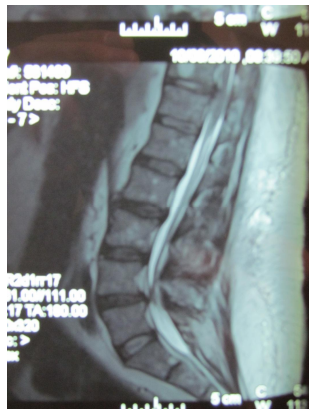Orthopedist's findings

- 4/5 strength right EHL, 5/5 knee extension
- Symmetrically decreased patellar reflexes
- Achilles reflexes intact
- The patient is ambulating with cane and did fall twice before using cane

MRI

- Extruded disc material from t11/12 narrowing spinal canal to 5mm and distorting the conus medullaris
- L2/3 narrowing to 8mm with bilateral recess stenosis
- L4/5 annular bulging, facet arthropathy, and congenital spinal stenosis 7mm midline, small synovial cyst on the right





Orthopedist's synopsis

- Recommended series of epidurals and physical therapy, lacking relief recommended decompression laminectomy with fusion L4/5
- Patient wanted 2nd opinion and was set up with neurosurgeon
- Neurosurgeon recommended decompression laminectomy L4/5

Dr. Cox

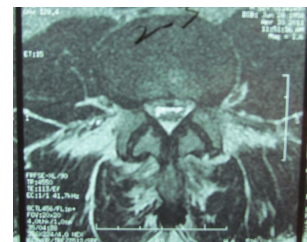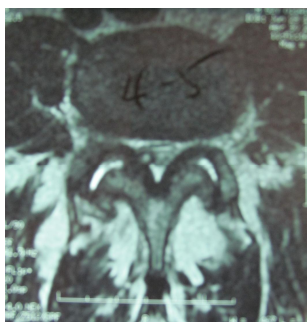
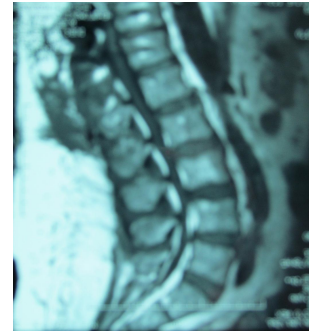- I had stayed in touch with patient thru this process. The patient and his family were concerned about which route to pursue, so I recommended we see Dr. Cox for a consult.
- Dr. Cox immediately was concerned with the T12/L1 area and recommended we consult with a neurosurgeon that he works with.

Dr. Cox

- Decompression laminectomy and fusion was performed at T11/12.
- The patient was braced and went thru physical therapy and did return to his office job.
- Right dorsiflexion remained 4/5 and due to deconditioning. The patient walked with a cane if he had to go for longer distances.

Dr. Cox

- 5 months after surgery the patient had an episode of lower back, buttock and right shin pain after he did some work in the yard.
- He saw the surgeon who repeated MRI.
- Degenerative spondylolisthesis L4/5 and modest stenosis at L2/3
- He recommended epidurals, and Dr. Cox was consulted again.



Dr. Cox's recommendations

- Russian stimulation to the right anterior tibialis muscle, FD to L2/3 and L4/5 levels
- Continue with rehab exercises
- Dr. Cox emphasized to the patient that some deficits would remain regardless of care and that a conservative approach may be helpful before resorting to more surgery.

Treatment

- We initiated care outlined by Dr. Cox.
- Initially the patient was seen two times per week for 6 weeks and now once per week for the past 12 weeks.
- He rarely uses his cane anymore; he still notices some right shin and buttocks pain but nothing sharp.
- He has had two minor exacerbations , both times working in the yard and overdoing the lifting.

Conclusion

- The patient is very pleased with where he is; he understands he may need eventual intervention at L4/5 but is stable at this time and is working on his weight and conditioning.
- The key to this case was Dr. Cox; the family was so impressed with the thorough examination and the careful explanation of the problem. The patient went into the surgery with confidence that he did not have before.